

**Tasks for students of International faculty,
specialty of “Dentistry”
“The locomotor system”**

Topic. Bones of the pelvic girdle. Bones of the free lower limb.

1. Because of a fall a 70-year-old man had a femur fracture. In what part of femur do fractures happen the most often?

A. Middle

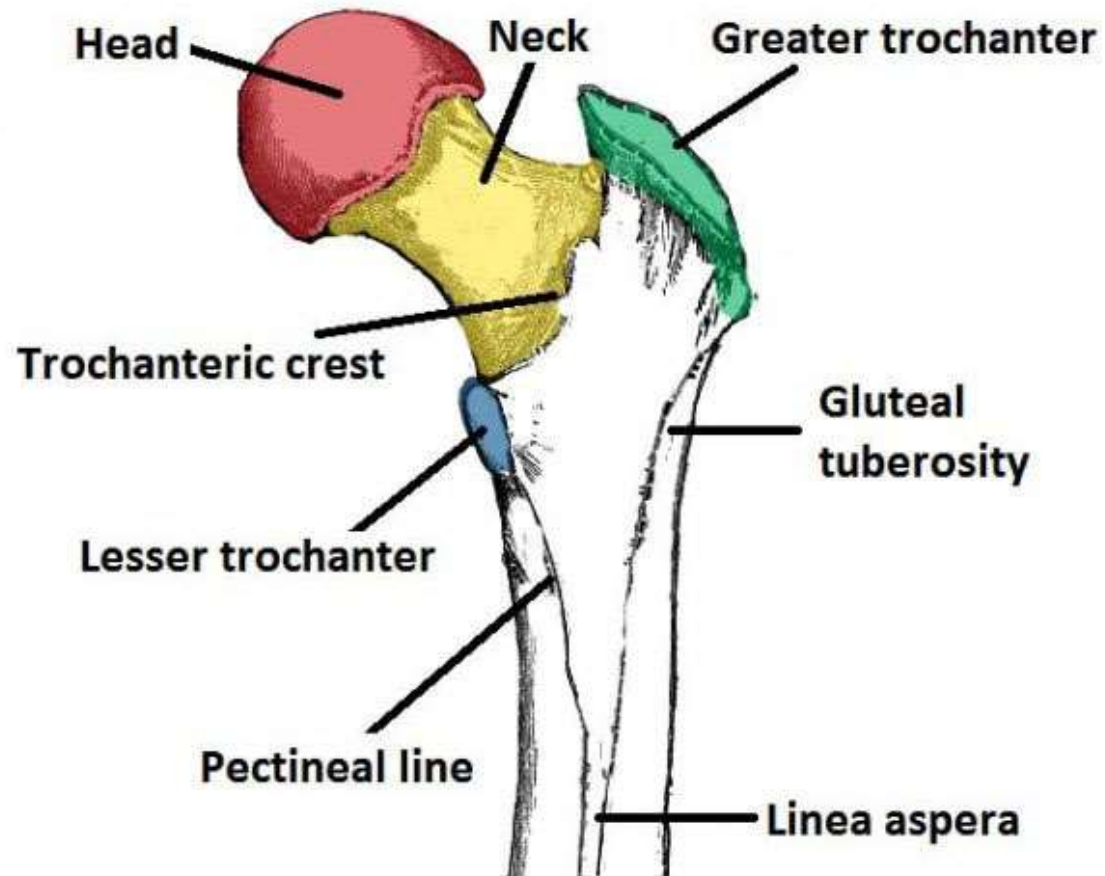
B. Neck

C. The upper third

D. The lower third

E. Condylar head

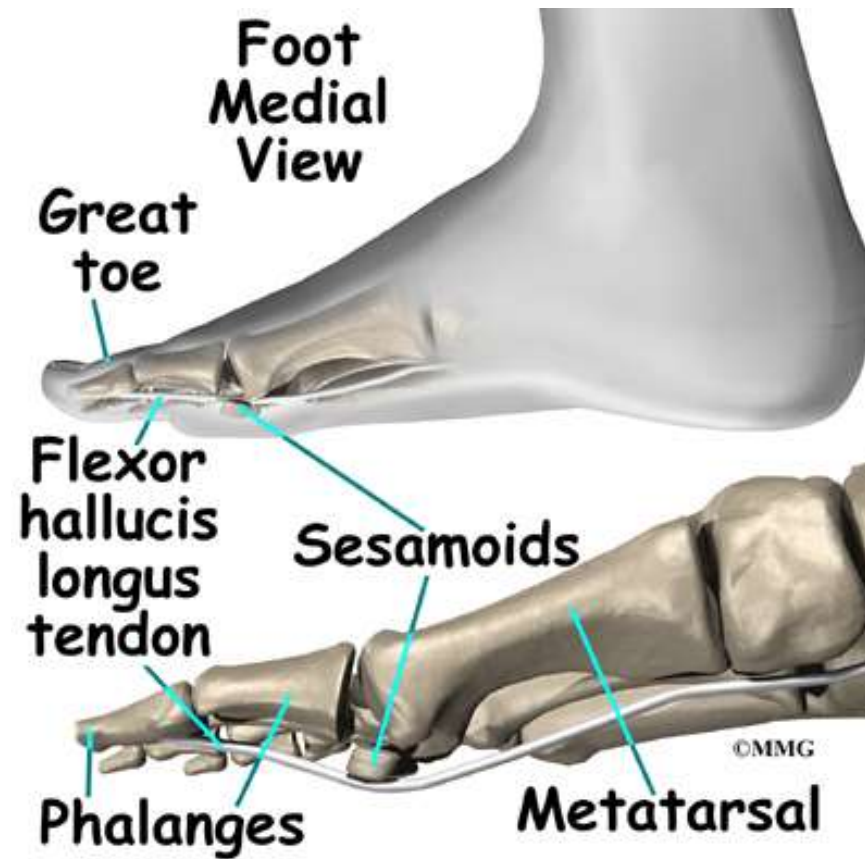B. Neck



3. During a football match a player-injured a knee joint. A roentgenogram shows the fracture of the bone, which is in the thickness of the quadriceps muscle of the thigh tendon. To what group of bones does this bone refer?

- A. Sesamoid bones
- B. Flat bones
- C. Tubular bones
- D. Pneumatic bones
- E. Mixed bones

A. Sesamoid bones



4. After collision of two cars a driver got deformation of the middle third of the left crus, intensive pain, especially in attempt to move the left crus. Ends of the trihedral bone come out of the wound, hemorrhage is increasing. What bone can be injured?

A. Tibia

B. Fibula

C. Femur

D. Patella

E. Talus

A. Tibia

